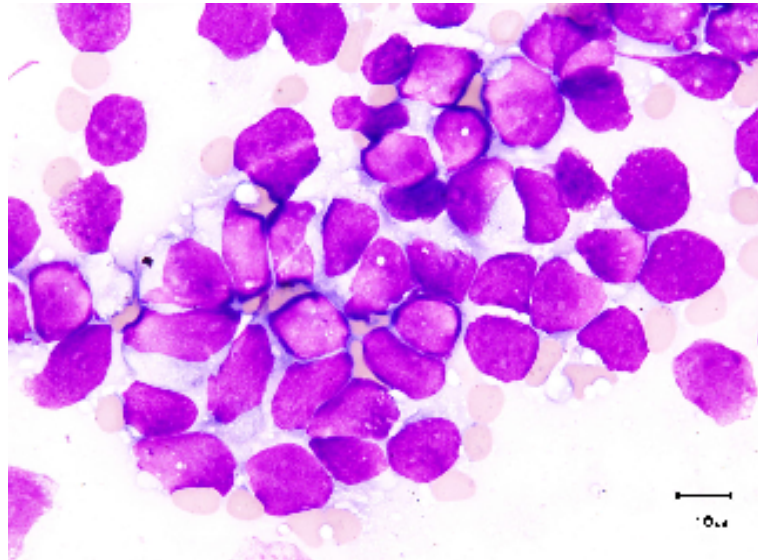
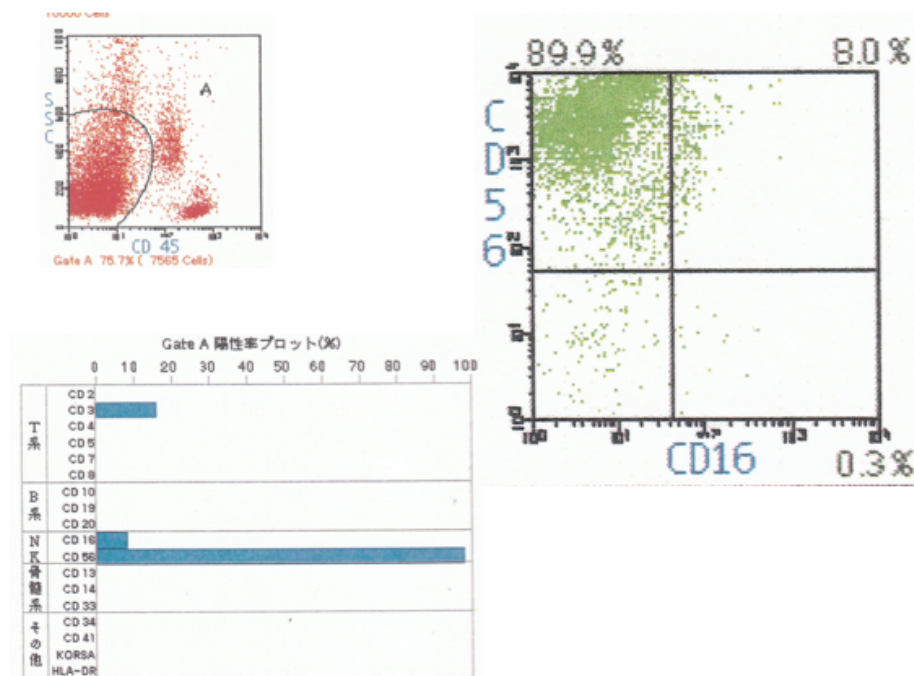


Aggressive NK cell Lymphoma



Bone Marrow aspiration shows a typical appearance of NK malignant cells which membrane represent the immunological phenotype of NK cells.



Kunio Hayashi, Hirakata Kohsai Hospital

E-mail : kunio-h@po.sphere.ne.jp