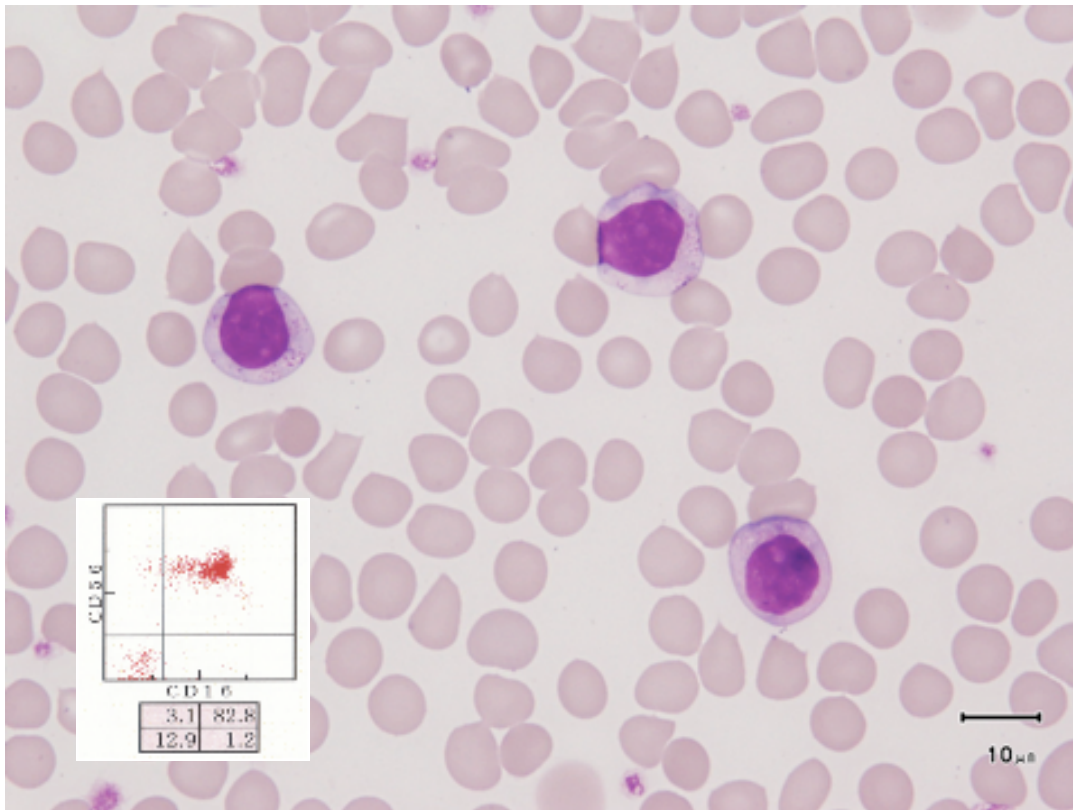
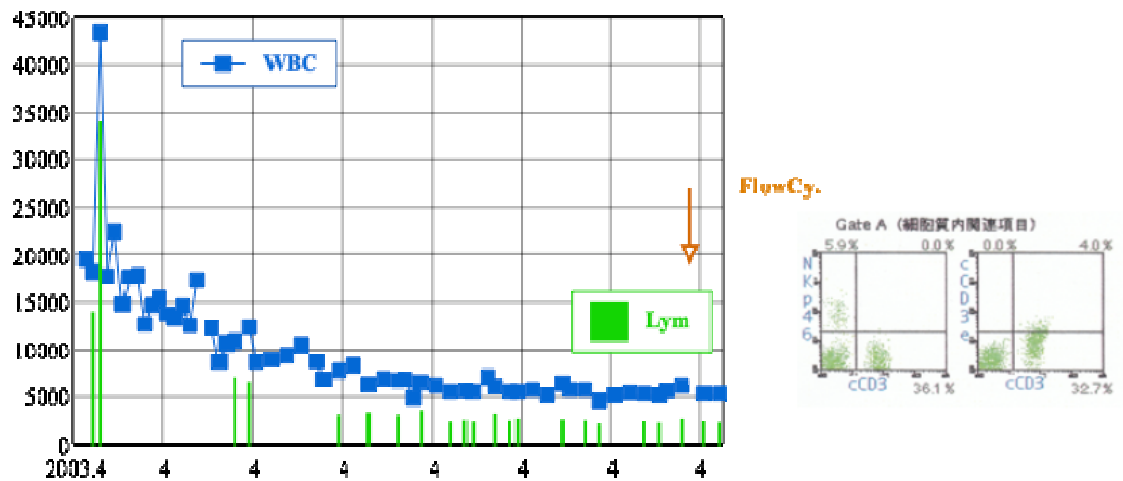


Chronic Lymphoproliferative disorders of NK-cell



NK cells with small granules in the peripheral blood.



NK cells disappeared completely in three years and the complete remission has been continuing without becoming to an aggressive NK cell disorder.

Kunio Hayashi, Hirakata Kohsai Hospital

E mail : kunio-h@po.sphere.ne.jp